

# Radiology Images

## PAEDIATRIC ABDOMEN

Manal Niazi and M. Ashraf Farooq

Radiology Department

Social Security Hospital, Islamabad Medical and Dental College

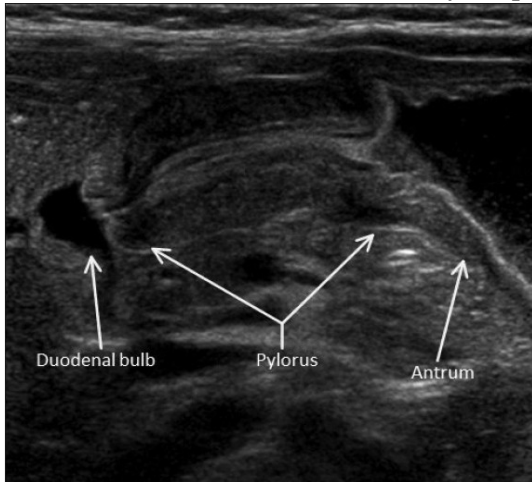


Image1a:Ultrasound Abdomen -Hypertrophic Pyloric Stenosis

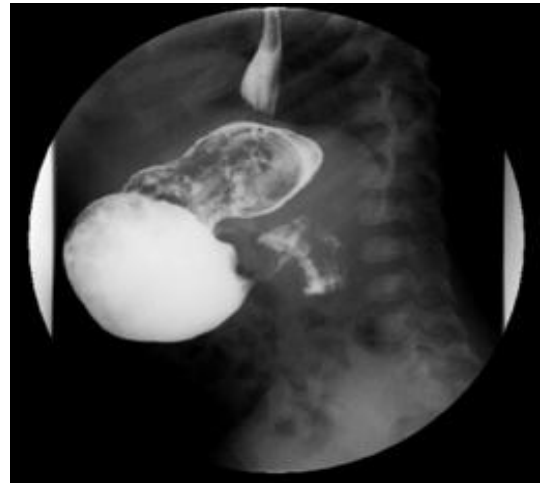

Image 1 b:Barium meal of the same patient- Hypertrophic Pyloric Stenosis.

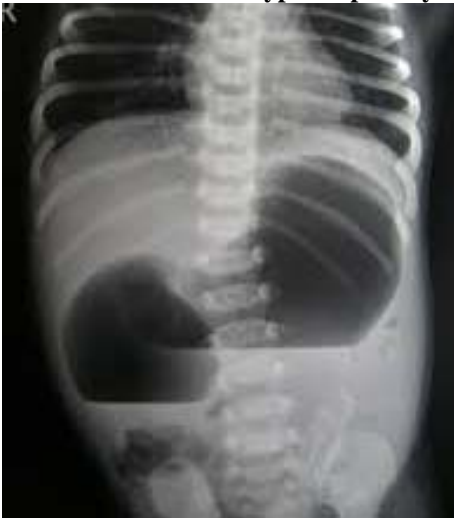

Image 2a:Plain X ray Abdomen Errect-Duodenal Atresia( Double bubble sign).

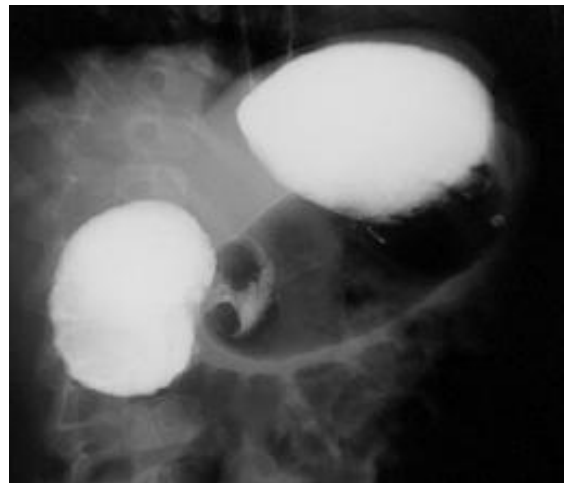


Image 2 b: Barium Meal of the same patient-Duodenal Atresia

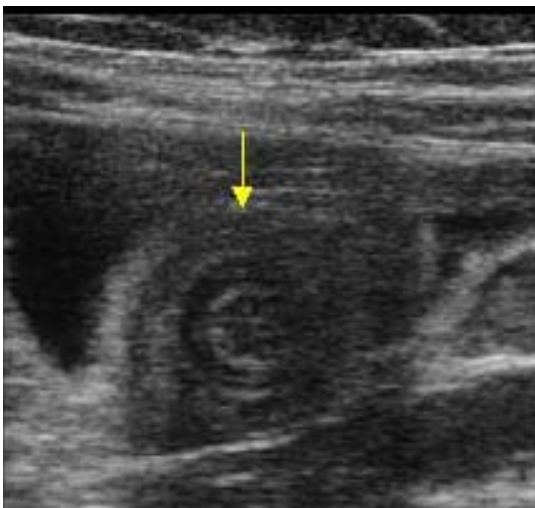
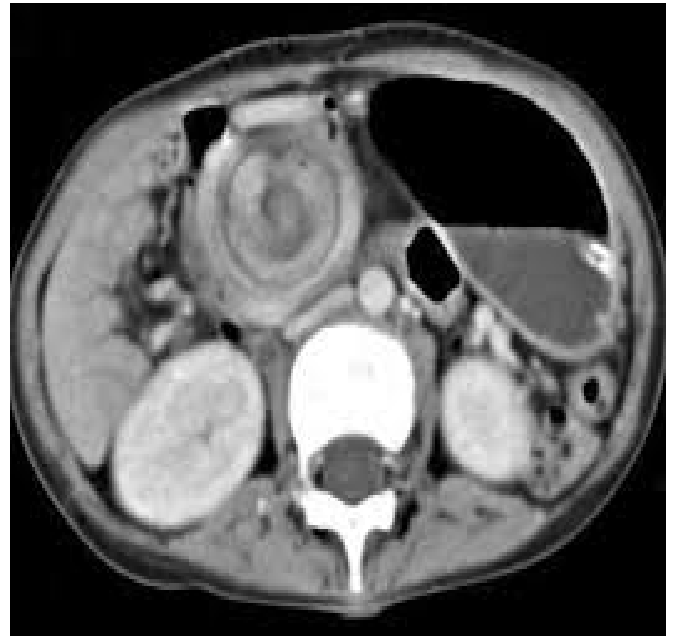
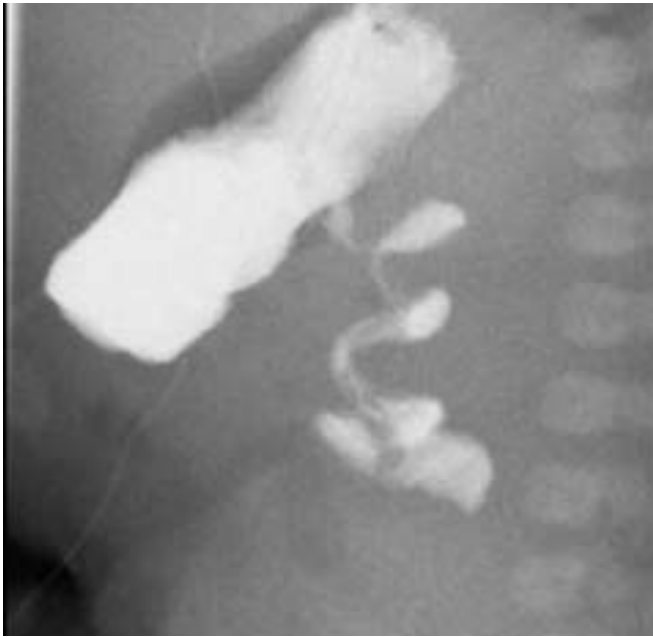


Image 3 a:Ultrasound Abdomen -Intussusception(target sign

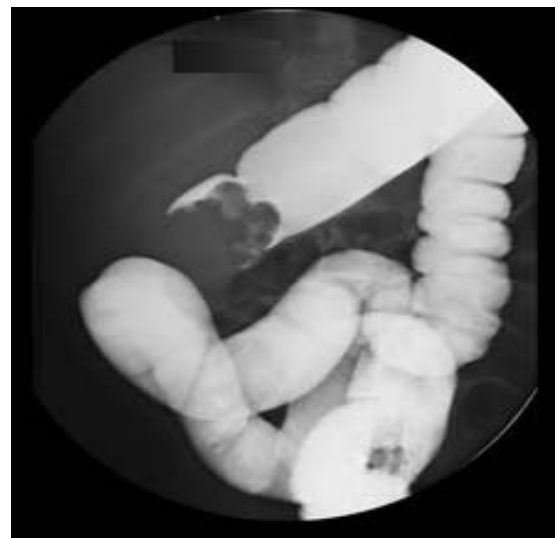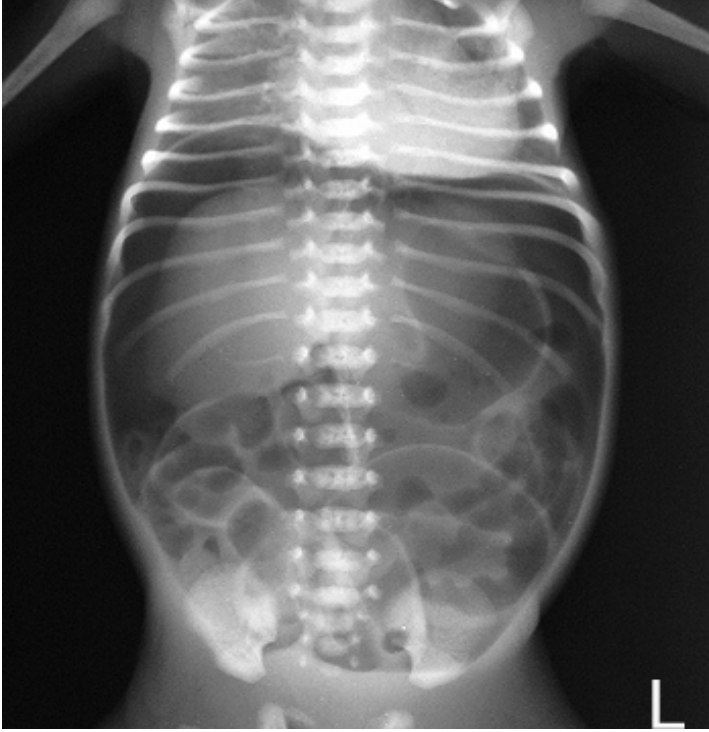


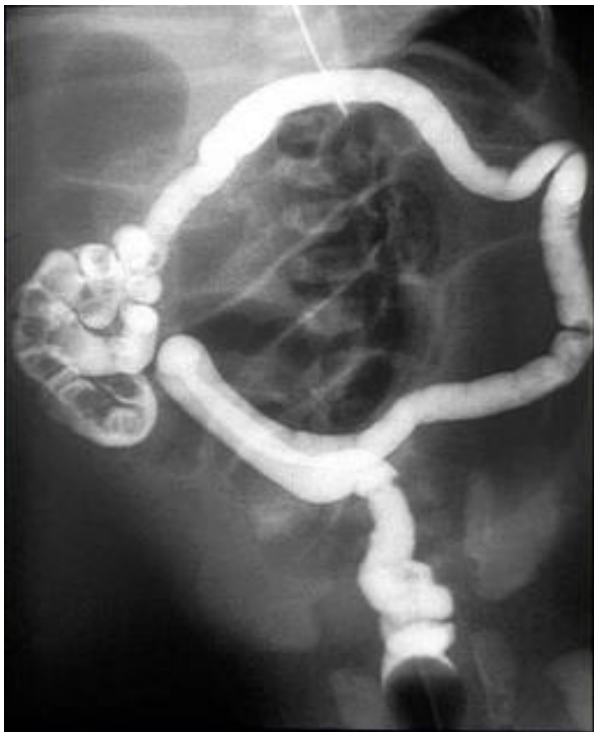Image 3 b:Barium Enema of same patient- Intussusception.



**Image4a : Contrast Meal and Follow Through (lateral view)- Midgut Volvulus (cork screw appearance).**

**Image 4b: CECT abdomen - Midgut Volvulus (whirl pool sign).**



**Image5 : Meconium Ileus. Contrast enema showing microcolon.**

**Image6:X ray Abdomen Supine-Pneumoperitoneum (foot ball sign and rigler's sign).**